

# GSM 900 MHz Microwave Radiation-Induced Alterations of Insulin Level and Histopathological Changes of Liver and Pancreas in Rat

Mortazavi S. M. J.<sup>1,2\*</sup>, Owji S. M.<sup>3</sup>, Shojaei-fard M. B.<sup>9,2</sup>, Ghader-Panah M.<sup>4</sup>, Mortazavi S. A. R.<sup>5</sup>, Tavakoli-Golpayegani A.<sup>6</sup>, Haghani M.<sup>2</sup>, Taeb S.<sup>2</sup>, Shokrpour N.<sup>7</sup>, Koochi O.<sup>8</sup>

## ABSTRACT

**Background:** The rapidly increasing use of mobile phones has led to public concerns about possible health effects of these popular communication devices. This study is an attempt to investigate the effects of radiofrequency (RF) radiation produced by GSM mobile phones on the insulin release in rats.

**Methods:** Forty two female adult Sprague Dawley rats were randomly divided into 4 groups. Group 1 were exposed to RF radiation 6 hours per day for 7 days. Group 2 received sham exposure (6 hours per day for 7 days). Groups 3 and 4 received RF radiation 3 hours per day for 7 days and sham exposure (3 hours per day), respectively. The specific absorption rate (SAR) of RF was 2.0 W/kg.

**Results:** Our results showed that RF radiations emitted from mobile phone could not alter insulin release in rats. However, mild to severe inflammatory changes in the portal spaces of the liver of rats as well as damage in the cells of islet of Langerhans were observed. These changes were linked with the duration of the exposures.

**Conclusion:** RF exposure can induce inflammatory changes in the liver as well causing damage in the cells of islet of Langerhans.

## Keywords

Mobile Phones, Electromagnetic Fields (EMFs), Radiofrequency (RF), Insulin Release, Rat

## Introduction

Radiofrequency (RF) radiation has long been used for different types of information exchange. Mobile phones which are low power, single channel two-way radios, emit signals via electromagnetic waves. Widespread use and increased popularity of these modern communication devices have caused a growing public concern about possible health effects of electromagnetic fields (EMFs).[1-5] Although mobile phones and mobile base stations emit the same type of radiation, the role of mobile phones in human exposures is estimated to be significantly higher than that of the towers. Although the output power of towers is two to three orders of magnitude greater than that of mobile phones, the phones are held just a few centimeters from sensitive parts of the body such as the brain and the eyes. It is estimated that

<sup>1</sup>Professor of Medical Physics, Medical Physics and Medical Engineering Department, School of Medicine, Shiraz University of Medical Sciences, Shiraz, Iran

<sup>2</sup>Ionizing and Non-ionizing Radiation Protection Research Center (INIR-PRC), Shiraz University of Medical Sciences, Shiraz, Iran

<sup>3</sup>Pathology Department, School of Medicine, Shiraz University of Medical Sciences, Shiraz, Iran

<sup>4</sup>Department of Radiology, School of Paramedical Sciences, Shiraz University of Medical Sciences, Shiraz, Iran

<sup>5</sup>Medical Student, School of Medicine, Shiraz University of Medical Sciences, Shiraz, Iran

<sup>6</sup>Standard Organization, Tehran, Iran

<sup>7</sup>Professor, School of Paramedical Sciences, Shiraz University of Medical Sciences, Shiraz, Iran

<sup>8</sup>Department of Laboratory Animals, School of Medicine, Shiraz University of Medical Sciences, Shiraz, Iran

<sup>9</sup>Department of Physiology, Fasa University of Medical Sciences, Fasa, Iran

\*Corresponding author: SMJ Mortazavi, Ph.D Professor of Medical Physics, Medical Physics & Medical Engineering Department, Ionizing and Non-ionizing Radiation Protection Research Center (INIRPRC), Shiraz University of Medical Sciences  
E-mail: mmortazavi@sums.ac.ir

approximately 50-70% of the output power of a phone is absorbed by the user.[6]

The bioeffects of exposure to electromagnetic fields on the function of different glands of endocrine system such as pineal, [7] pituitary gland,[8-10] adrenal,[11] hypothalamus,[8] and thyroid gland,[12] as well as of the endocrine pancreas,[13, 14] testicles,[15-17] and ovaries,[8] have been widely investigated. Insulin plays important roles such as maintenance of sufficient energy stores to allow for development, growth, and reproduction and serving as a feedback regulator of plasma glucose.[18] Although it is known that long term exposure to extremely low frequency electromagnetic fields (ELFEMF) can be associated with biological effects such as increased size of pancreatic islets and decreased glucose level [19], the effects of short-term exposure to radiofrequency radiations used in mobile communication (900/1800 MHz) on the insulin level and the structure of liver and pancreas are not clearly understood. Over the past years, our laboratory has focused on studying the health effects of exposure of laboratory animals and humans to some common and/or occupational sources of electromagnetic fields including mobile phones,[12, 20-26].

## Materials and Methods

### Animals

Forty two female adult Sprague Dawley rats (200-250 g) were randomly divided into 4 groups of 14 or 7 animals each. The rationale for this design was this point that there was no exposure in the both of sham-exposure groups. Therefore, we could pool the results of these two sham exposure groups. The animals were kept in special cages with controlled temperature ( $22 \pm 2^\circ\text{C}$ ), humidity ( $50 \pm 10\%$ ), and lighting (fluorescent lighting was provided for 12 h daily). All animal experiments were considered and approved by the Animal Experimentation Ethics Committee of Shiraz University of Medical Sciences prior to com-

mencing work. The animals in the first group were exposed to RF radiation 6 hours per day for 7 days. The 2nd group received sham exposure (6 hours per day for 7 days). The 3rd and 4th groups received RF radiation 3 hours per day for 7 days and sham exposure (3 hours per day), respectively.

### Exposure (Radiofrequency Irradiation)

A Nokia 1200 GSM mobile phone in talk mode was used for RF irradiation. During the RF exposure, the animals were immobilized by placing their body through Plexiglas restrainers. The distance between the antenna of the mobile phone and animal's head was 5 cm. The specific absorption rate (SAR) of RF was 2.0 W/kg.

### Insulin Measurement and Histological Studies

Insulin level was measured by using Mercodia rat insulin kit. On day 9 all animals were sacrificed and the liver and pancreas were excised. These organs were cut by sagittal plane and stored in buffered 10% formalin solution. After routine processing, paraffin blocks were prepared for liver and pancreas separately. Sections with 5 $\mu\text{m}$  thickness were stained with hematoxylin and eosin (H & E) respectively and were studied under light microscope.

### Statistical analysis

The difference among the mean insulin levels of different groups was evaluated by the non-parametric tests. A value of  $P < 0.05$  (2-sided) was considered statistically significant.

## Results

The mean insulin level in the 1st group before exposure to RF radiation was  $0.34 \pm 0.22$   $\mu\text{UI/dl}$  (Table 1), while after exposure (6 hours per day for 7 days) it was  $0.16 \pm 0.05$   $\mu\text{UI/dl}$  ( $P = 0.001$ ). On the other hand, the mean insulin level in the 2nd group before sham exposure to RF radiation was  $0.53 \pm 0.37$   $\mu\text{UI/dl}$ , while af-

ter sham exposure (6 hours per day for 7 days) it was  $0.26 \pm 0.17 \mu\text{UI/dl}$  ( $P=0.028$ ). In animals of the 3rd group, the mean insulin level before exposure to RF radiation was  $0.22 \pm 0.26 \mu\text{UI/dl}$ , while after exposure (3 hours per day for 7 days) it was  $0.23 \pm 0.14 \mu\text{UI/dl}$  ( $P=0.423$ ). On the other hand, the mean insulin level in the 4th group before sham exposure to RF radiation was  $0.28 \pm 0.28 \mu\text{UI/dl}$ , while after sham exposure (6 hours per day for 7 days) it was  $0.27 \pm 0.15 \mu\text{UI/dl}$  ( $P=0.917$ ). In spite of the observed differences, the baseline (before the exposure) insulin levels in all groups were within the acceptable levels for these animals and the differences in the baseline insulin levels were not statistically significant.

### Histological Findings

In this study, as shown in Figure 1, no histological abnormalities were observed in the liver of the sham exposed groups (groups 2 and 4). The histological sections of the liver of group 1 (6 h exposure per day for 7 days) showed severe infiltration of mononuclear cells, mainly lymphocytes in the portal spaces of the hepatic lobules with penetration of the cells into the limiting plate of portal space Figure 2. The sections of the liver in the group 3 (3 h exposure per day for 7 days) showed mild

mononuclear cellular infiltration in the portal spaces with no penetration into the limiting plates Figure 3. In both of the above groups no histologic abnormalities were observed in the central veins, hepatocyte cytoplasm and nuclei, liver sinusoids and kuppfer cells.

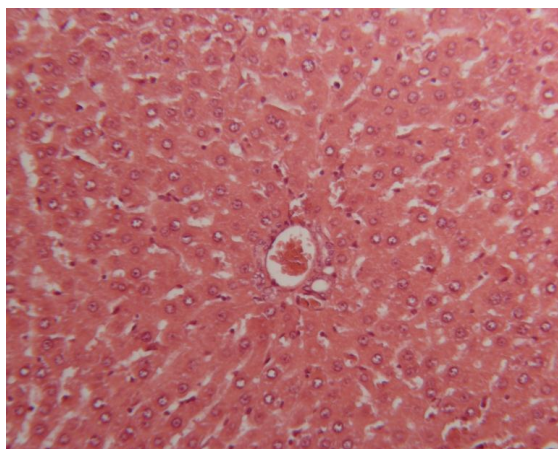
No histological abnormalities were observed in the pancreas of the sham exposed groups (Figure 4). The histopathologic changes of the pancreas in the group 2 (6 h exposure per day for 7 days) showed moderate diffuse dissociation of the endocrine cells of the islet cells of pancreas from each other (Figure 5).

The sections of the pancreas in the group 4 (3 h exposure per day for 7 days) showed mild focal dissociation of the cells in the islet cells of the Langerhance. The exocrine portion of the pancreas and pancreatic duct and blood vessels in both of groups 2 and 4 were normal (Figure 6).

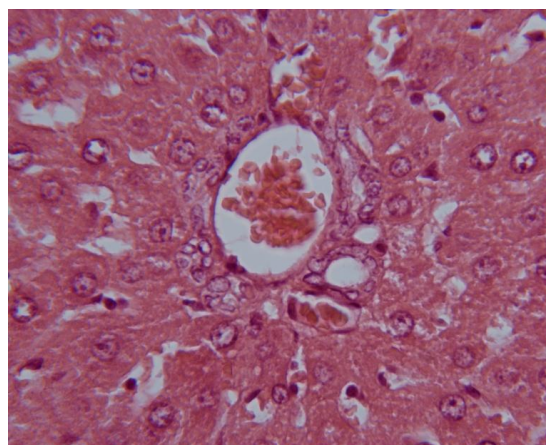
### Discussion

#### Insulin Level

Findings of this study showed that exposure to RF radiation (6 hours per day for 7 days) significantly decreased the mean insulin level in the 1st group ( $0.34 \pm 0.22 \mu\text{UI/dl}$  before exposure and  $0.16 \pm 0.05 \mu\text{UI/dl}$  after exposure,



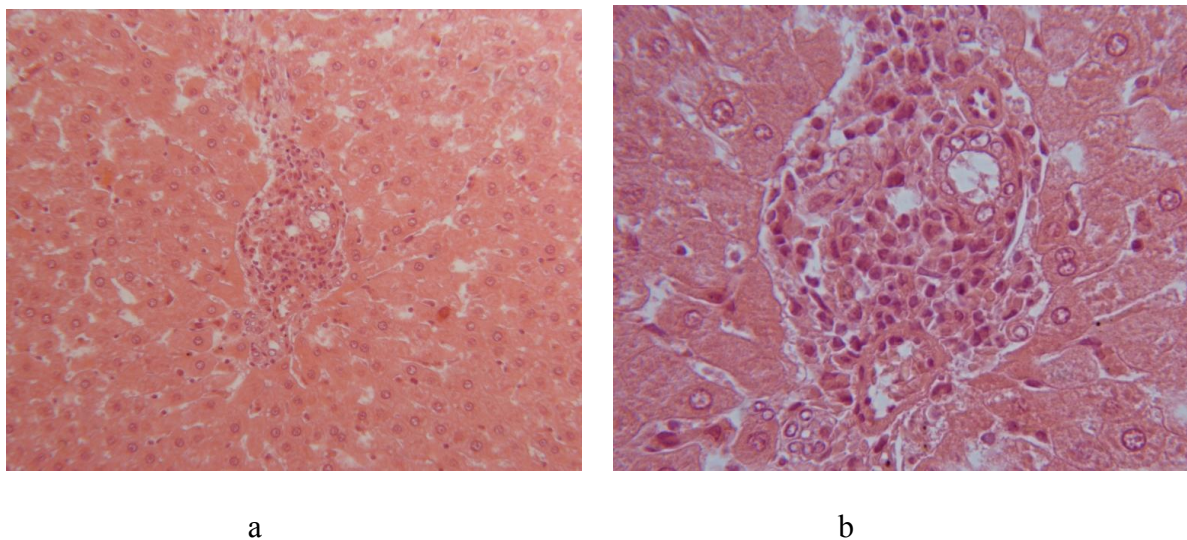
a



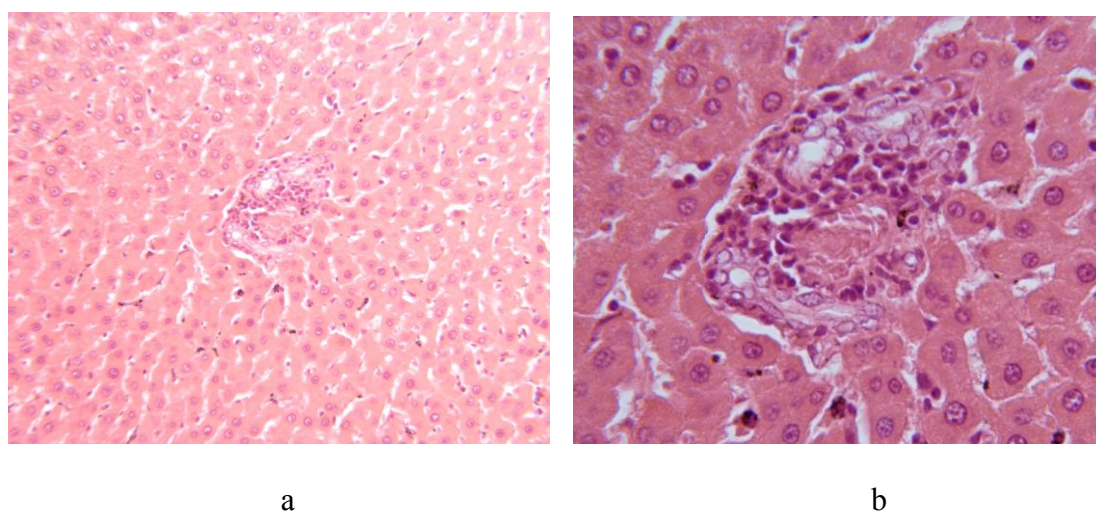
b

**Figure 1:** Micrographs of liver of the sham exposed groups (groups 2 and 4). No histological abnormalities can be observed in the histological sections (a  $\times 160$ , b  $\times 400$ ).





**Figure 2:** Micrographs of the liver of group 1 (6 h exposure per day for 7 days). Severe infiltration of mononuclear cells, mainly lymphocytes in the portal spaces of the hepatic lobules with penetration of the cells into the limiting plate of portal space is observed. (a  $\times 160$ , b  $\times 400$ ).

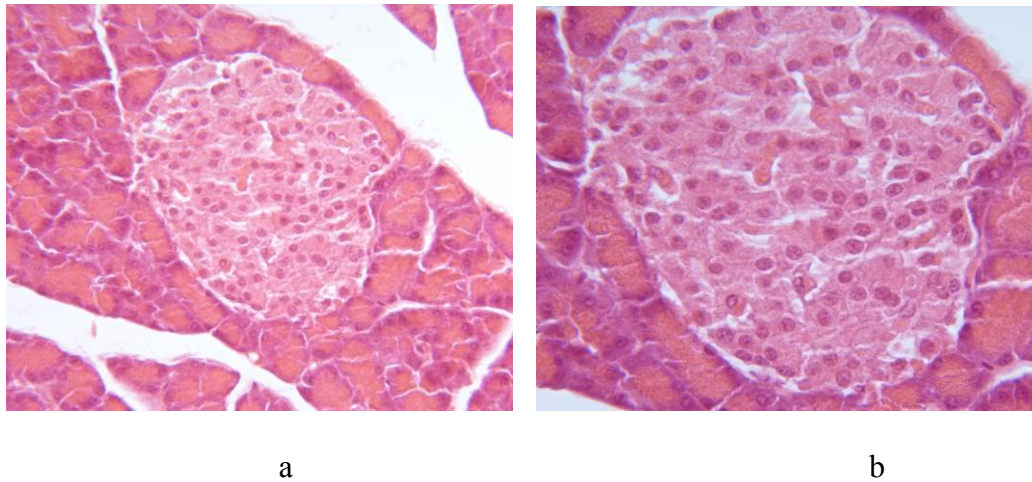


**Figure 3:** The sections of the liver in the group 3 (3 h exposure per day for 7 days) show mild mononuclear cellular infiltration in the portal spaces with no penetration into the limiting plates. No histologic abnormalities can be observed in the central veins, hepatocyte cytoplasm and nuclei, liver sinusoids and kuppfer cells (a  $\times 160$ , b  $\times 400$ ).

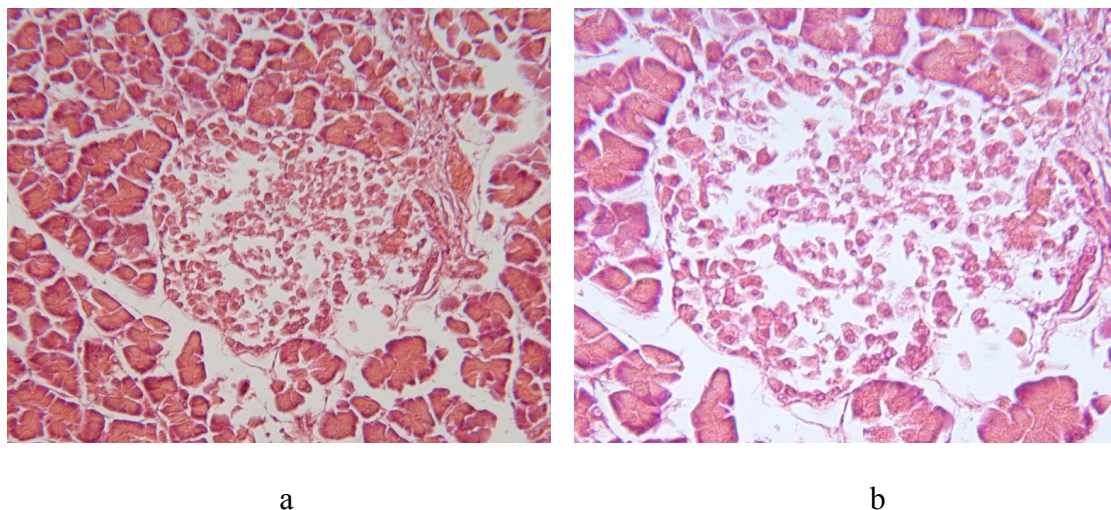
$P=0.001$ ). It is worth mentioning that the mean insulin level in the 2nd group that were sham exposed to RF radiation (6 hours per day for 7 days) also decreased after sham exposure ( $0.53 \pm 0.37$   $\mu\text{UI/dl}$  before sham exposure and  $0.26 \pm 0.17$   $\mu\text{UI/dl}$  after sham exposure,  $P=0.028$ ).

Interestingly decreasing the exposure time

from 6 hours per day to 3 hours per day (for 7 days) did not affect the insulin level (there was no any statistical significant difference between before exposure/sham exposure and after exposure/sham exposure insulin levels). To the best of our knowledge, our study is the first survey to assess the associations between exposure to 900 MHz GSM mobile phone ra-



**Figure 4:** The sections of the pancreas in the sham exposed group showing normal acini and normal islet cells of the Langerhans (a  $\times 160$ , b  $\times 250$ ).

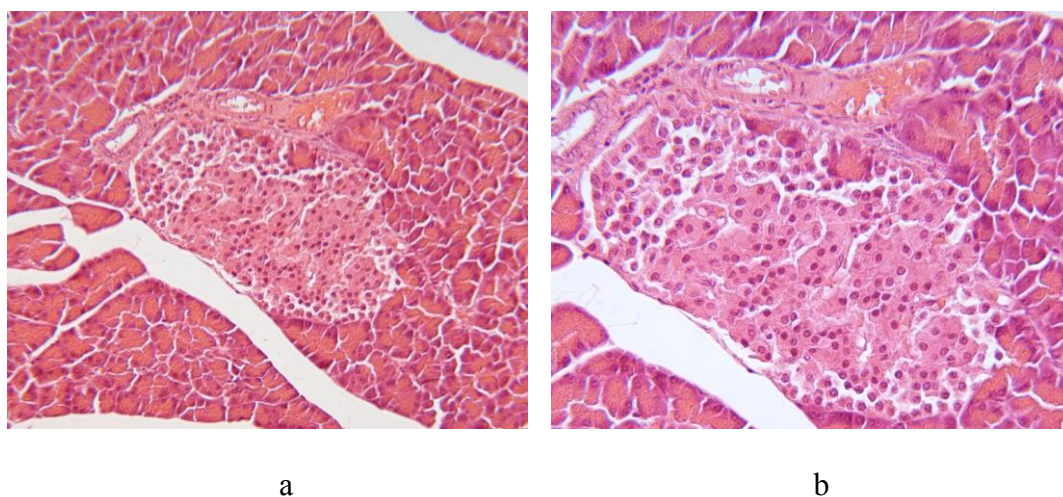


**Figure 5:** The sections of the pancreas in the group 2 (6 h exposure per day for 7 days) showing dissociation of most of the islet cells of the Langerhans (a  $\times 160$ , b  $\times 250$ ).

diations and alterations in the levels of insulin hormone as well as the histopathological changes of liver and pancreas. However, there are some published reports on the effects of extremely low frequency radiations (ELF) on insulin level in laboratory animals. Our findings are in contrast with those reported by Gholampour et al. who showed that the insulin level of the exposed rats (continuous exposure to 50 Hz extremely low frequency EMF 24 h/day for 135 days) was increased. According to their report this increase was associated with

the increased size of pancreatic Langerhans islets.[19] It is worth mentioning that our study and that conducted by Gholampour et al. are different in many ways. First of all, we used 900 MHz GSM mobile phone radiations while 50 Hz extremely low frequency EMF was used in the study of Gholampour and his colleagues. On the other hand, the duration of exposure in our study was much shorter than that of Gholampour et al. (3 or 6 hours per day for 7 days versus continuous exposure to 50 Hz extremely low frequency EMF 24 h/day for 135 days).





**Figure 6:** The sections of the pancreas in the group 4 (3 h exposure per day for 7 days) show mild focal dissociation of the cells in the islet cells of the Langerhance. Exocrine portion of the pancreas and pancreatic duct and blood vessels in both of groups 2 and 4 are normal (a  $\times 160$ , b  $\times 250$ ).

These basic variations in the study design and methods can easily explain the observed different findings. Interestingly, Sakurai et al had previously suggested that the exposure to extremely low frequency magnetic fields (continuous exposure to 60 Hz ELF, magnetic flux densities of 400  $\mu\text{T}$ , 1 mT or 5 mT for either 10 or 15 min) can be clinically used as a novel inhibitory method of excessive insulin secretion in treatment of type 2 diabetes.[27] Bahaoddini et al. also studied the effects of exposure to magnetic field (exposure to 50Hz ELF, 500 $\mu\text{T}$ , 10 h/day for 2 months) on energy metabolism in rats, divided 45 adult male rats into 3 equal groups. Serum insulin and cholesterol levels in the EMF exposed group were less than those of other groups, while serum glucose level was significantly higher in the exposed animals. These authors also reported that based on their findings exposure to EMF has a potential role in clinical use.

### Histological Findings

This study showed that RF radiation emitted from mobile phones can induce mild to severe inflammatory changes in the portal spaces of the liver of rat depending on the duration of

the exposure from 3 to 6 hours per day for 7 days. No definite hepatic histological changes have been reported in the literature so far. However, regarding the bioeffects of exposure to extremely low frequency electromagnetic fields, there are some published reports. Gholampour et al. have previously shown that continuous exposure of rats to 50 Hz extremely low frequency EMF 24 h/day for 135 days alters insulin secretion by affecting the structure of pancreas. [19]\_ENREF\_34.

Also the RF radiation of mobile phones can induce damage in the cells of islet of Langerhans as separation of the cells from each other with mild focal to moderate and diffuse depending on the duration of exposures from 3 to 6 hours per day for 7 days. Further large-scale research is required to clarify the extent of alterations caused by mobile phone use on the insulin level in humans.

### Conclusion

Based on the results obtained in this study it can be concluded that mobile phones signal strength cannot significantly alter the accuracy of home blood glucose monitors. More studies using blood glucose monitors and mobile

phones made by different manufactures are needed to better understand the role of mobile phone signal strength on the occurrence of EMI.

### Acknowledgment

This research was supported by the Center for Research in Radiation Sciences (CRRS). The authors are grateful to the staff of the SUMS laboratory animal for their technical support.

### Conflict of Interest

The authors hereby confirm that none of them have any kinds of "Conflict of Interest" (such as financial, personal, political, or academic) that would potentially affect their judgment.

### References

1. Stewart A, Rao JN, Middleton JD, Pearmain P, Evans T. Mobile telecommunications and health: report of an investigation into an alleged cancer cluster in Sandwell, West Midlands. *Perspect Public Health*. 2012;**132**:299-304. doi.org/10.1177/1757913911427375. PubMed PMID: 23111085.
2. Mohler E, Frei P, Frohlich J, Braun-Fahrlander C, Roosli M. Exposure to radiofrequency electromagnetic fields and sleep quality: a prospective cohort study. *PLoS One*. 2012;**7**:e37455. doi.org/10.1371/journal.pone.0037455. PubMed PMID: 22624036. PubMed PMCID: 3356284.
3. Kismali G, Ozgur E, Guler G, Akcay A, Sel T, Seyhan N. The influence of 1800 MHz GSM-like signals on blood chemistry and oxidative stress in non-pregnant and pregnant rabbits. *Int J Radiat Biol*. 2012;**88**:414-9. doi.org/10.3109/09553002.2012.661517. PubMed PMID: 22280439.
4. Swerdlow AJ, Feychting M, Green AC, Leeka Kheifets LK, Savitz DA. Mobile phones, brain tumors, and the interphone study: where are we now? *Environ Health Perspect*. 2011;**119**:1534-8. doi.org/10.1289/ehp.1103693. PubMed PMID: 22171384. PubMed PMCID: 3226506.
5. Frei P, Mohler E, Braun-Fahrlander C, Frohlich J, Neubauer G, Roosli M. Cohort study on the effects of everyday life radio frequency electromagnetic field exposure on non-specific symptoms and tinnitus. *Environ Int*. 2012;**38**:29-36. doi.org/10.1016/j.envint.2011.08.002. PubMed PMID: 21982030.
6. Slesin L, editor. Public Concerns over Microwave Radiation in the US: Comparing the Perceived Health Risks of Phones and Towers. International Conference on Cell Tower Siting Linking Science & Public Health: Salzburg. P. 2000.
7. Touitou Y, Selmaoui B. The effects of extremely low-frequency magnetic fields on melatonin and cortisol, two marker rhythms of the circadian system. *Dialogues Clin Neurosci*. 2012;**14**:381-99. PubMed PMID: 23393415. PubMed PMCID: 3553569.
8. Dundar B, Cesur G, Comlekci S, Songur A, Gokcimen A, Sahin O, et al. The effect of the prenatal and post-natal long-term exposure to 50 Hz electric field on growth, pubertal development and IGF-1 levels in female Wistar rats. *Toxicol Ind Health*. 2009;**25**:479-87. doi.org/10.1177/0748233709345942. PubMed PMID: 19783573.
9. Lisi A, Ledda M, Rosola E, Pozzi D, D'Emilia E, Giuliani L, et al. Extremely low frequency electromagnetic field exposure promotes differentiation of pituitary corticotrope-derived AtT20 D16V cells. *Bioelectromagnetics*. 2006;**27**:641-51. doi.org/10.1002/bem.20255. PubMed PMID: 16838272.
10. Forgacs Z, Somosy Z, Kubinyi G, Sinay H, Bakos J, Thuroczy G, et al. Effects of whole-body 50-Hz magnetic field exposure on mouse Leydig cells. *ScientificWorldJournal*. 2004;**4**:83-90. doi.org/10.1100/tsw.2004.182. PubMed PMID: 15517106.
11. Gagnon ZE, Newkirk C, Conetta JA, Sama MA, Sisselman S. Teratogenic effect of broad-band electromagnetic field on neonatal mice (*Mus musculus*). *J Environ Sci Health A Tox Hazard Subst Environ Eng*. 2003;**38**:2465-81. doi.org/10.1081/ESE-120024449. PubMed PMID: 14533916.
12. Mortavazi S, Habib A, Ganj-Karami A, Samimi-Doost R, Pour-Abedi A, Babaie A. Alterations in TSH and Thyroid Hormones following Mobile Phone Use. *Oman Med J*. 2009;**24**:274-8. doi.org/10.5001/omj.2009.56. PubMed PMID: 22216380. PubMed PMCID: 3243874.
13. Sakurai T, Terashima S, Miyakoshi J. Effects of strong static magnetic fields used in magnetic resonance imaging on insulin-secreting cells. *Bioelectromagnetics*. 2009;**30**:1-8. doi.org/10.1002/bem.20433. PubMed PMID: 18521845.
14. Sakurai T, Yoshimoto M, Koyama S, Miyakoshi J. Exposure to extremely low frequency magnetic fields affects insulin-secreting cells. *Bioelectromagnetics*. 2008;**29**:118-24. doi.org/10.1002/

- bem.20370. PubMed PMID: 17929267.
15. Wang XW, Ding GR, Shi CH, Zhao T, Zhang J, Zeng LH, et al. Effect of electromagnetic pulse exposure on permeability of blood-testicle barrier in mice. *Biomed Environ Sci*. 2008;**21**:218-21. doi.org/10.1016/S0895-3988(08)60032-X. PubMed PMID: 18714819.
  16. Meo SA, Arif M, Rashied S, Khan MM, Vohra MS, Usmani AM, et al. Hypospermatogenesis and spermatozoa maturation arrest in rats induced by mobile phone radiation. *J Coll Physicians Surg Pak*. 2011;**21**:262-5. PubMed PMID: 21575531.
  17. Tenorio BM, Jimenez GC, de Morais RN, Peixoto CA, de Albuquerque Nogueira R, da Silva VA, Jr. Evaluation of testicular degeneration induced by low-frequency electromagnetic fields. *J Appl Toxicol*. 2012;**32**:210-8. doi.org/10.1002/jat.1680. PubMed PMID: 21452164.
  18. Porte D. Central regulation of energy homeostasis the key role of insulin. *Diabetes*. 2006;**55**:S155-S60. doi.org/10.2337/db06-S019.
  19. Gholampour F, Javadifar T, Owji S, Bahaoddini A. Prolonged exposure to extremely low frequency electromagnetic field affects endocrine secretion and structure of pancreas in rats. *International Journal of Zoological Research*. 2011;**7**:338. doi.org/10.3923/ijzr.2011.393.400.
  20. Mortazavi SM, Motamedifar M, Namdari G, Taheri M, Mortazavi AR, Shokrpour N. Non-linear adaptive phenomena which decrease the risk of infection after pre-exposure to radiofrequency radiation. *Dose Response*. 2014;**12**:233-45. doi.org/10.2203/dose-response.12-055.Mortazavi. PubMed PMID: 24910582. PubMed PMCID: 4036396.
  21. Mortazavi SM, Taeb S, Dehghan N. Alterations of visual reaction time and short term memory in military radar personnel. *Iran J Public Health*. 2013;**42**:428-35. PubMed PMID: 23785684. PubMed PMCID: 3684731.
  22. Mortazavi SM, Rouintan MS, Taeb S, Dehghan N, Ghaffarpanah AA, Sadeghi Z, et al. Human short-term exposure to electromagnetic fields emitted by mobile phones decreases computer-assisted visual reaction time. *Acta Neurol Belg*. 2012;**112**:171-5. doi.org/10.1007/s13760-012-0044-y. PubMed PMID: 22426673.
  23. Mortazavi S, Mosleh-Shirazi M, Tavassoli A, Taheri M, Mehdizadeh A, Namazi S, et al. Increased Radioresistance to Lethal Doses of Gamma Rays in Mice and Rats after Exposure to Microwave Radiation Emitted by a GSM Mobile Phone Simulator. *Dose Response*. 2013;**11**:281-92. doi.org/10.2203/dose-response.12-010.Mortazavi. PubMed PMID: 23930107. PubMed PMCID: 3682203.
  24. Mortazavi S, Mosleh-Shirazi M, Tavassoli A, Taheri M, Bagheri Z, Ghalandari R, et al. A comparative study on the increased radioresistance to lethal doses of gamma rays after exposure to microwave radiation and oral intake of flaxseed oil. *Iranian Journal of Radiation Research*. 2011;**9**:9-14.
  25. Mortazavi SM, Daiee E, Yazdi A, Khiabani K, Kavousi A, Vazirinejad R, et al. Mercury release from dental amalgam restorations after magnetic resonance imaging and following mobile phone use. *Pak J Biol Sci*. 2008;**11**:1142-6. doi.org/10.3923/pjbs.2008.1142.1146. PubMed PMID: 18819554.
  26. Mortazavi SM, Ahmadi J, Shariati M. Prevalence of subjective poor health symptoms associated with exposure to electromagnetic fields among university students. *Bioelectromagnetics*. 2007;**28**:326-30. doi.org/10.1002/bem.20305. PubMed PMID: 17330851.
  27. Sakurai T, Koyama S, Komatsubara Y, Jin W, Miyakoshi J. Decrease in glucose-stimulated insulin secretion following exposure to magnetic fields. *Biochem Biophys Res Commun*. 2005;**332**:28-32. doi.org/10.1016/j.bbrc.2005.04.091. PubMed PMID: 15896294.