

New MRI Finding in Migraineurs: Mesial Temporal Sclerosis

Bagheri M. H.^{1,2}, Jalli R.^{1*}, Hoseyni Moghadam A.¹

ABSTRACT

Background: Based on our experience, a noticeable number of migraineurs without history of epilepsy disclose mesial temporal sclerosis (MTS) on their brain MRI.

Objective: This prospective study was conducted to assess the frequency of MTS in migraineurs and also determine the ratio of unilateral and bilateral cases.

Material and Methods: In this cross sectional study, the frequency of MTS in MRI of 84 migraine patients, who had symptoms for at least 2 years, assessed. Brain MRI was done with T1 and T2 weighted protocols. Two radiologists separately interpreted findings, defining MTS as presence of any of hippocampal atrophy, increased T2 signal of hippocampus, decreased T1 signal of hippocampus or loss of internal architecture. Patients who radiologists had not agreement on their diagnoses excluded. Stat analysis done using 'N - 1' chi squared test.

Results: Eleven patients were excluded due to non-accordant interpretation of MRI findings by the two examining radiologists. MTS was detected in 14 out of 73 patients (19%). Bilateral involvement of mesial temporal lobe was seen in 6 (8%) patients (M: 67%, F: 33%). Five cases (7%) had unilateral left MTS (M: 67%, F: 33%) while 3 (4%) were affected with right-sided MTS (M: 33%, F: 67%). These findings highly suggest association of MTS and Migraine (P-value <0.0001).

Conclusion: While MTS is a prevalent finding in migraineurs, incidental finding of MTS in MRI should suspect physicians of migraine as well as temporal lobe epilepsy. MTS can be proposed as an etiology of migraine but most likely, consequence of it.

Citation: Bagheri MH, Jalli R, Hoseyni Moghadam A. New MRI Finding in Migraineurs: Mesial Temporal Sclerosis. *J Biomed Phys Eng.* 2020;10(4):459-466. doi: 10.31661/jbpe.v0i0.887.

Keywords

Hippocampal Sclerosis; Migraine Disorders; Magnetic Resonance Imaging; Epilepsy, Temporal Lobe

Introduction

Migraine is a primary headache disorder ranking as the 7th specific cause of disability in the Global Burden of Disease Survey 2010 [1]. It is estimated to affect 12% of the Caucasian general population [2], with a two-times higher likelihood in women compared to men [3]. Epidemiological studies in Iran documented a prevalence of 1.7% among 7-11 year old school children [4] and 6.1% in adolescent girls [5], increasing to a range of 7.4-27.6% in the adult population [6, 7]. The approximate median onset age of 25 years [8] further highlights the importance of personal and socio-economic burdens [9]. Apart from the attack-related disability, even in the pain-free

¹MD, Medical Imaging Research Center, Shiraz University of Medical Sciences, Shiraz, Iran

²MD, Department of Radiology and Imaging Sciences (A.P., R.S., D.S.R., M.B., T.E.C., D.A.B.), National Institutes of Health Clinical Center, Bethesda, Maryland

*Corresponding author:
R. Jalli
Medical Imaging Research Center, Shiraz University of Medical Sciences, Shiraz, Iran
E-mail: Jalli@sums.ac.ir

Received: 9 January 2018
Accepted: 14 March 2018

phase, the anticipatory anxiety of experiencing a migraine attack disrupts the overall well-being [10]. Thus, migraine poses a substantial negative impact on the daily social activities, productivity and quality of life of patients [11, 12].

According to the International Classification of Headache Disorders, migraineurs suffer from typically unilateral and pulsating recurrent headaches with moderate to severe intensity lasting for 4-72 hours, which might be accompanied by nausea and/or photophobia and phonophobia. In the clinical subtype with aura, preceding transient focal neurological symptoms are characteristic. [1] Episodic manifestations of migraine are believed to be a consequence of neurovascular cascade of events induced by a variety of triggers, such as glare, loud noise, odors, foods, hormonal changes, head trauma, and nitric oxide [13]. Diagnosis of migraine is fundamentally based on history, clinical examination, and by exclusion of relevant secondary causes of headache [14]. However, as the condition progresses in some individuals and the process of “clinical transformation” occurs, anatomic changes are ultimately observed in neuroimaging evaluations. These alterations include stroke lesions, deep white matter hyperintensities, and cortical changes in specific areas, which are reportedly associated with aura and attack frequency [15, 16].

MTS frequency in normal population (neither epilepsy, nor migraine sufferers) evaluated by Moore et al. is 1% [17]. Based on our experience, a noticeable number of migraineurs without history of epilepsy present with the incidental finding of mesial temporal sclerosis (MTS) revealed in MRI. MTS is the most common finding in drug resistant, chronic temporal lobe epilepsies [18]. Although the mechanism remains unclear, some evidences suggest that MTS might be a cause, as well as a result of seizure [19]. To facilitate better understanding of migraine pathophysiology, we designed this pilot study to assess the frequen-

cy of MTS in migraine patients and determine the ratio of unilateral and bilateral cases. To the best of our knowledge, there is no similar study in the literature and the presented data are novel.

Material and Methods

In this cross sectional study, 84 patients suffering from migraine headaches for at least the past 2 years were selected via simple sampling. The patients had been visited by an attending neurologist and brain MRI without contrast was subsequently requested based on clinical indications. We excluded individuals with previous history of epilepsy, head trauma, brain surgery, and brain radiotherapy. Imaging was performed using either a Phillips Intra 1.5T MRI scanner or a Siemens 1.5T MAGNETOM Avanto MRI, in the radiology department of a university-affiliated center, Nemazee Hospital, Shiraz, Iran. Two attending radiologists, who were unaware of the underlying disease of the participants, separately interpreted MRI images. They defined MTS as presence of any hippocampal atrophy, increased T2 signal of hippocampus, and decreased T1 signal of hippocampus or loss of internal architecture. Ethics Committee of Shiraz University of Medical Sciences approved our study. Data are represented descriptively. Data analyzed by the “*N-1*” Chi-squared test and P-value < 0.05 were considered significant.

Results

A total of 84 eligible patients with the average age of 28.7 years (16 - 58), who were afflicted with migraine headache for 2 to 16 years, participated in this study. Eleven patients were ultimately excluded as a result of non-accordant interpretation of their MRI findings by the two examining radiologists. Forty-one women and 32 men constituted the remaining 73 cases.

MTS was detected in 14 out of 73 patients (19%), with an age range of 26 to 51 years (34.3). Although we set 2 years of migraine

headache as inclusion criteria, the minimum duration of migraine at the time of MTS detection was 5 years. Bilateral involvement of mesial temporal lobe was seen in 6 patients (M: 67%, F: 33%). Five cases had unilateral left MTS (M: 60%, F: 40%), while 3 were affected by right-sided MTS (M: 33%, F: 67%) (Figures 1 and 2). Our findings highly suggest the association of MTS and Migraine (P-value

<0.0001).

Discussion

Mesial temporal sclerosis is the scarring of the medial temporal lobes of the brain. It is recognized as the most common pathologic finding in the temporal lobe epilepsy [20]. The underlying mechanism of MTS development in seizure is explained through prolonged neu-

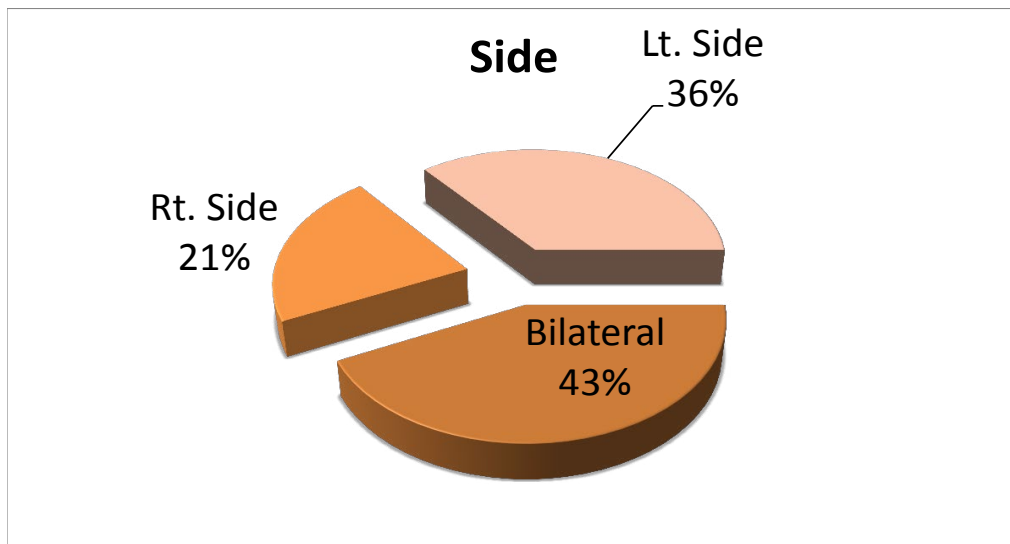


Figure 1: Frequency of bilateral and unilateral MTS in 73 patients.

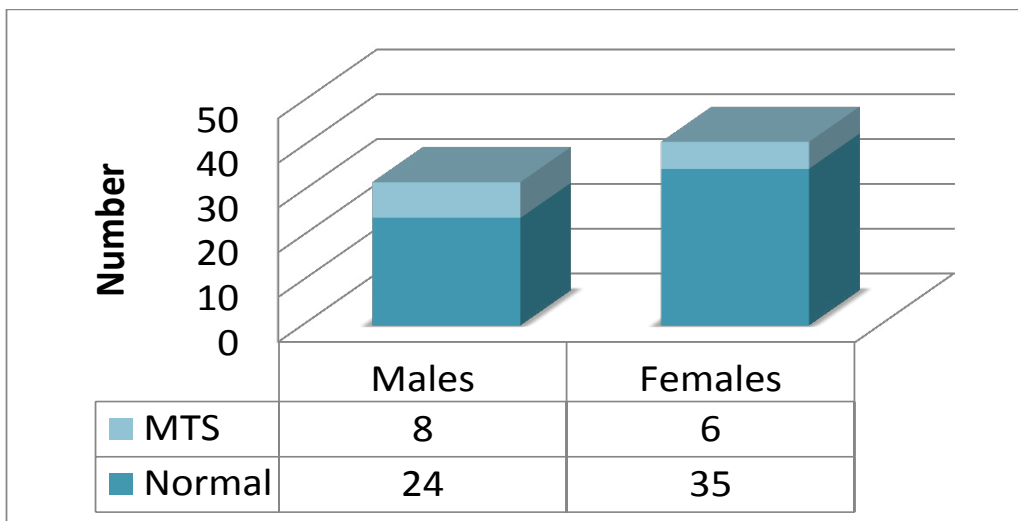


Figure 2: Gender Distribution

ronal depolarization caused by the release of excitatory amino acids. As a result, an influx of cytotoxic amounts of calcium occurs, which eventually leads to sclerosis [20]. Therefore, if the seizures last longer, the development of MTS is more likely [21]. Consequent to the cellular damage, scar tissue forms especially in hippocampus, a region of temporal lobe. This process is followed by atrophy [20]. MRI is the imaging of choice for evaluation of MTS, since it is a noninvasive modality and unveils the localization of deficits and structural abnormalities to a great extent [22]. Although there is specific software to detect MTS such as NeuroQuant, Azab et al. have shown this software is as sensitive as neuroradiologists in detection of MTS [23].

To shed light on the pathophysiology and evolution of migraine, we designed this novel study and evaluated the frequency and features of MTS in otherwise healthy migraine patients underwent MRI examination. We were motivated by the incidental detection of MTS in some of the migraineurs referring to our radiology department. Our study showed that as high as 19% of non-epileptic migraine patient fulfill the criteria of MTS diagnosis on MRI, and 8.2% are expected to have bilateral manifestations. Any association between migraine and MTS is nonexistent in current literature. Herein, we discuss the possible explanations to the presence of MTS in the migrainous brain.

Both migraine and epilepsy are classified as neurological chronic disorders with episodic manifestations (CDEM), which are described by recurrent attacks of nervous system dysfunction and normal baseline function during intervals [24]. Migraine and epilepsy are clinical diagnostic challenges and often difficult to be differentiated from one another, partially due to their common trigger factors and overlapping signs and symptoms [25]. For instance, patients with mesial temporal lobe epilepsy often experience unilateral headaches ipsilateral to the side of the temporal lobe ab-

normality [26]. Furthermore, migraine and epilepsy are comorbid, as an individual with one disorder is more likely to be affected by the others compared to the chance in the general population [27]. Thus, misdiagnosis should be taken into account, especially in cases treated with antiepileptic medications [28].

Alternative theories have been proposed to clarify the comorbidity of these two paroxysmal disorders. Firstly, the unidirectional explanation indicates that brain ischemia and injury are caused by migraine predisposes patients to epilepsy. On the other hand, epilepsy is a potential cause of migraine by activating the trigeminovascular system [24]. The bidirectional explanation is based on the shared environmental and genetic risk factors. Mutations in the three known genes for familial hemiplegic migraine (FHM), which are responsible for dysfunction of ion channels, can cause epilepsy [25]. This genetic association points to a common pathophysiological mechanism in migraine and epilepsy. This brings us to the hyperexcitability hypothesis. It is defined as the altered excitability status of cerebral cortex, and has long been established in epilepsy. Nevertheless, this concept was later introduced by Welch with regards to migraine [29, 30]. Neuronal excitability is blamed on channelopathy, mitochondrial dysfunction, and reduced magnesium levels [31]. We previously referred to the influx of calcium ion as a result of prolonged neuronal depolarization. Accordingly, development of MTS might be possible in patients purely affected by migraine.

Another insult linked to the development of MTS is prolonged febrile seizures in early childhood. It is reported that 30% of epileptic patients with MTS have a positive history compared to only 6% of patients without MTS [32]. However, it seems that regardless of the fever, hypoxia and hypoglycemia induce the hippocampal damage similar to that caused by prolonged seizures [32]. It is noteworthy, that migraine is a well-known risk factor for brain ischemia and stroke [33].

Another possibility is the sporadic asymptomatic MTS without any correlation to migraine. Kobayashi et al. studied first-degree relatives of patients with familial mesial temporal lobe epilepsy. Eighteen out of 52 individuals had MRI signs of hippocampal atrophy, while 14 of these cases had hippocampal sclerosis. The authors concluded that MRI evidence of hippocampal sclerosis is not always associated with seizure and probably genetic factors play a significant role [34]. But we can add to their conclusion that MTS could be the result of other diseases like migraine.

In an interesting study, Benbadis et al. studied the incidence of MTS in MRI of normal population from 5 to 50 years old without history of seizures, mental illness, or alcohol abuse. The criteria of MTS diagnosis were hippocampal atrophy and increased hippocampal T2 signal. Twenty-nine subjects out of the overall 204 participants (14%) manifested abnormal and asymmetric mesial temporal structures in line with unilateral MTS. Nineteen (9.3%) met only the criteria of hippocampal atrophy, while two (1%) showed only T2 signal abnormalities. Only eight ones (4%) had both criteria in MRI. The authors claimed that these finding count for 'false positives' and MRI evidence for MTS are best interpreted based on clinical context [35]. They supported their conclusion by citing another studies stating the specificity of 86% for MRI in diagnosis of hippocampal sclerosis [36]. But the patients who had suffered from headaches categorized as normal population in Benbadis's study and because their inclusion criteria for MRI were as followed: "Performed for vague, non-specific symptoms (headaches, dizziness), or screening for metastases or cerebral aneurysms." Although it is not mentioned how many of patients suffered from headaches, probably most of their cases were afflicted by headaches. Contrary to this high percentage, another study by Moore et al. found that only 2 of 207 nonepileptic patients underwent MRI examination for hearing loss had incidental

finding of hippocampal sclerosis [17].

We cannot rule out false positives in our study. Yet, considering the 19% incidence in our study, possibility of migraine partial attribution cannot be excluded as well. It was better if we had a control group and added alcohol consumption as an exclusion criterion. Furthermore, it was the best if we had used the epilepsy protocol. Banderas et al. also reported four patients with psychogenic nonepileptic seizures, who had referred for surgical intervention of epilepsy. In these patients, MRI diagnosis of MTS was misleading, since all patients had normal interictal EEG and no risk factor epilepsy [37]. As systematic reviews have shown, incidence of epilepsy is vaguely higher in men [38, 39]. In our research, among migraine sufferers, 25% of men and just 15% of women had MTS. Putting these two patterns together may attenuate the hypothesis that some of migarainous patients may have some grades of seizure component.

Conclusion

MTS is a prevalent finding in migraineurs. Incidental finding of MTS in MRI should suspect physicians of migraine as well as temporal lobe epilepsy. MTS can be proposed as an etiology of migraine but most likely, consequence of it.

Acknowledgment

The authors would like to thank Shiraz University of Medical Sciences, Shiraz, Iran and also Center for Development of Clinical Research of Nemazee Hospital for statistical and editorial assistance.

This article certified by Ethic Committee of Shiraz University of Medical Sciences. Ethic Code: IR.SUMS.REC.1394.F1057.

Conflict of Interest

None

References

1. Headache Classification Committee of the In-

- ternational Headache S. The International Classification of Headache Disorders, 3rd edition (beta version). *Cephalalgia*. 2013;**33**:629-808. doi: 10.1177/0333102413485658. PubMed PMID: 23771276.
2. Younger DS. Epidemiology of Migraine. *Neurol Clin*. 2016;**34**:849-61. doi: 10.1016/j.ncl.2016.06.011. PubMed PMID: 27719997.
 3. Bolay H, Ozge A, Saginc P, Orekici G, Uluduz D, Yalin O, et al. Gender influences headache characteristics with increasing age in migraine patients. *Cephalalgia*. 2015;**35**:792-800. doi: 10.1177/0333102414559735. PubMed PMID: 25424708.
 4. Ayatollahi S, Khosravi A. The study of clinical characteristics of Shiraz school children suffering from migraine and tension type headache (2002-2003). *J Kermanshah Uni Med Sci*. 2004;**8**:25-32.
 5. Ayatollahi SM, Moradi F, Ayatollahi SA. Prevalences of migraine and tension-type headache in adolescent girls of Shiraz (southern Iran). *Headache*. 2002;**42**:287-90. doi: 10.1046/j.1526-4610.2002.02082.x. PubMed PMID: 12010386.
 6. Ayatollahi SMT, Sahebi L, Haghghi AB. Epidemiologic and clinical characteristics of migraine and tension-type headaches among hospitals staffs of Shiraz (Iran). *Acta Med Iran*. 2009:115-20.
 7. Rabiee B, Zeinoddini A, Kordi R, Yunesian M, Mohammadinejad P, Mansournia MA. The Epidemiology of Migraine Headache in General Population of Tehran, Iran. *Neuroepidemiology*. 2016;**46**:9-13. doi: 10.1159/000441146. PubMed PMID: 26580919.
 8. Stewart WF, Wood C, Reed ML, Roy J, Lipton RB, Group AA. Cumulative lifetime migraine incidence in women and men. *Cephalalgia*. 2008;**28**:1170-8. doi: 10.1111/j.1468-2982.2008.01666.x. PubMed PMID: 18644028.
 9. Lipton RB, Bigal ME. The epidemiology of migraine. *Am J Med*. 2005;**118** Suppl 1:3S-10S. PubMed PMID: 15841882.
 10. Peres MF, Mercante JP, Guendler VZ, Corchs F, Bernik MA, Zukerman E, et al. Cephalalgia phobia: a possible specific phobia of illness. *J Headache Pain*. 2007;**8**:56-9. doi: 10.1007/s10194-007-0361-3. PubMed PMID: 17361383. PubMed PMCID: PMC3476114.
 11. Leonardi M, Raggi A, Bussone G, D'Amico D. Health-related quality of life, disability and severity of disease in patients with migraine attending to a specialty headache center. *Headache*. 2010;**50**:1576-86. doi: 10.1111/j.1526-4610.2010.01770.x. PubMed PMID: 21029083.
 12. Lanteri-Minet M, Duru G, Mudge M, Cottrell S. Quality of life impairment, disability and economic burden associated with chronic daily headache, focusing on chronic migraine with or without medication overuse: a systematic review. *Cephalalgia*. 2011;**31**:837-50. doi: 10.1177/0333102411398400. PubMed PMID: 21464078.
 13. Ward TN. Migraine diagnosis and pathophysiology. *Continuum (Minneapolis)*. 2012;**18**:753-63. doi: 10.1212/01.CON.0000418640.07405.31. PubMed PMID: 22868539.
 14. Dougherty C, Silberstein SD. Providing Care for Patients with Chronic Migraine: Diagnosis, Treatment, and Management. *Pain Pract*. 2015;**15**:688-92. doi: 10.1111/papr.12243. PubMed PMID: 25271173.
 15. Bigal ME, Lipton RB. Clinical course in migraine: conceptualizing migraine transformation. *Neurology*. 2008;**71**:848-55. doi: 10.1212/01.wnl.0000325565.63526.d2. PubMed PMID: 18779513.
 16. Maleki N, Becerra L, Brawn J, Bigal M, Burstein R, Borsook D. Concurrent functional and structural cortical alterations in migraine. *Cephalalgia*. 2012;**32**:607-20. doi: 10.1177/0333102412445622. PubMed PMID: 22623760. PubMed PMCID: PMC3846436.
 17. Moore KR, Swallow CE, Tsuruda JS. Incidental detection of hippocampal sclerosis on MR images: is it significant? *AJNR Am J Neuroradiol*. 1999;**20**:1609-12. PubMed PMID: 10543629.
 18. Blumcke I, Pauli E, Clusmann H, Schramm J, Becker A, Elger C, et al. A new clinicopathological classification system for mesial temporal sclerosis. *Acta Neuropathol*.

- 2007;**113**:235-44. doi: 10.1007/s00401-006-0187-0. PubMed PMID: 17221203. PubMed PMCID: PMC1794628.
19. Engel Jr J. Mesial temporal lobe epilepsy: what have we learned? *Neuroscientist*. 2001;**7**:340-52. doi: 10.1177/107385840100700410. PubMed PMID: 11488399.
 20. Deshpande S, Kashyap P, Dave D, Mukherji A. Mesial temporal sclerosis. *International Journal of Research in Medical Sciences*. 2016;**4**:5090-2.
 21. Liu Z, Mikati M, Holmes GL. Mesial temporal sclerosis: pathogenesis and significance. *Pediatric Neurol*. 1995;**12**:5-16. doi: 10.1016/0887-8994(94)00122-i. PubMed PMID: 7748361.
 22. Connor SE, Jarosz JM. Magnetic resonance imaging of patients with epilepsy. *Clin Radiol*. 2001;**56**:787-801. doi: 10.1053/crad.2001.0744. PubMed PMID: 11895296.
 23. Azab M, Carone M, Ying SH, Yousem DM. Mesial Temporal Sclerosis: Accuracy of NeuroQuant versus Neuroradiologist. *AJNR Am J Neuroradiol*. 2015;**36**:1400-6. doi: 10.3174/ajnr.A4313. PubMed PMID: 25907519.
 24. Haut SR, Bigal ME, Lipton RB. Chronic disorders with episodic manifestations: focus on epilepsy and migraine. *Lancet Neurol*. 2006;**5**:148-57. doi: 10.1016/S1474-4422(06)70348-9. PubMed PMID: 16426991. PubMed PMCID: PMC1457022.
 25. Haan J, Terwindt GM, Van Den Maagdenberg AM, Stam AH, Ferrari MD. A review of the genetic relation between migraine and epilepsy. *Cephalalgia*. 2008;**28**:105-13. doi: 10.1111/j.1468-2982.2007.01460.x. PubMed PMID: 18197881.
 26. Sprenger T, Borsook D. Migraine Changes the Brain—Neuroimaging Imaging Makes its Mark. *Curr Opin Neurol*. 2012;**25**:252-62. doi: 10.1097/wco.0b013e3283532ca3.
 27. De Simone R, Ranieri A, Marano E, Beneduce L, Ripa P, Bilo L, et al. Migraine and epilepsy: clinical and pathophysiological relations. *Neurol Sci*. 2007;**28** Suppl 2:S150-5. doi: 10.1007/s10072-007-0769-1. PubMed PMID: 17508163.
 28. Bigal ME, Lipton RB, Cohen J, Silberstein SD. Epilepsy and migraine. *Epilepsy Behav*. 2003;**4** Suppl 2:S13-24. PubMed PMID: 14527480.
 29. Welch KM, D'Andrea G, Tepley N, Barkley G, Ramadan NM. The concept of migraine as a state of central neuronal hyperexcitability. *Neurol Clin*. 1990;**8**:817-28. doi: 10.1016/s0733-8619(18)30319-0. PubMed PMID: 1979655.
 30. Aurora SK, Cao Y, Bowyer SM, Welch KM. The occipital cortex is hyperexcitable in migraine: experimental evidence. *Headache*. 1999;**39**:469-76. doi: 10.1046/j.1526-4610.1999.3907469.x. PubMed PMID: 11279929.
 31. Welch KM. Brain hyperexcitability: the basis for antiepileptic drugs in migraine prevention. *Headache*. 2005;**45** Suppl 1:S25-32. doi: 10.1111/j.1526-4610.2005.4501008.x. PubMed PMID: 15833087.
 32. Cendes F. Febrile seizures and mesial temporal sclerosis. *Curr Opin Neurol*. 2004;**17**:161-4. doi: 10.1097/00019052-200404000-00013. PubMed PMID: 15021243.
 33. Etmiman M, Takkouche B, Isorna FC, Samii A. Risk of ischaemic stroke in people with migraine: systematic review and meta-analysis of observational studies. *BMJ*. 2005;**330**:63. doi: 10.1136/bmj.38302.504063.8F. PubMed PMID: 15596418. PubMed PMCID: PMC543862.
 34. Kobayashi E, Li LM, Lopes-Cendes I, Cendes F. Magnetic resonance imaging evidence of hippocampal sclerosis in asymptomatic, first-degree relatives of patients with familial mesial temporal lobe epilepsy. *Arch Neurol*. 2002;**59**:1891-4. doi: 10.1001/archneur.59.12.1891. PubMed PMID: 12470176.
 35. Benbadis SR, Wallace J, Reed Murtagh F. MRI evidence of mesial temporal sclerosis in subjects without seizures. *Seizure*. 2002;**11**:340-3. doi: 10.1053/seiz.2001.0613. PubMed PMID: 12076108.
 36. Jackson GD, Berkovic SF, Tress BM, Kalnins RM, Fabinyi GC, Bladin PF. Hippocampal sclerosis can be reliably detected by magnetic resonance imaging. *Neurology*. 1990;**40**:1869-75. doi: 10.1212/wnl.40.12.1869. PubMed PMID: 2247236.
 37. Benbadis SR, Tatum WO, Murtagh FR, Vale

- FL. MRI evidence of mesial temporal sclerosis in patients with psychogenic nonepileptic seizures. *Neurology*. 2000;**55**:1061-2. doi: 10.1212/wnl.55.7.1061. PubMed PMID: 11061274.
38. Kotsopoulos IA, van Merode T, Kessels FG, De Krom MC, Knottnerus JA. Systematic review and meta-analysis of incidence studies of epilepsy and unprovoked seizures. *Epilepsia*. 2002;**43**:1402-9. doi: 10.1046/j.1528-1157.2002.t01-1-26901.x. PubMed PMID: 12423392.
39. Hauser WA, Annegers JF, Kurland LT. Incidence of epilepsy and unprovoked seizures in Rochester, Minnesota: 1935-1984. *Epilepsia*. 1993;**34**:453-68. doi: 10.1111/j.1528-1157.1993.tb02586.x. PubMed PMID: 8504780.