

Scope Assessment of Soft Tissue Injury within Polytrauma for Needs of Fortis System Injury Classification

Nikita Bobrov¹, Radoslav Morochovič², Ján Mandelík^{3*}

ABSTRACT

Background: The paper points out the importance of quantifying the extent and nature of organ and tissue injury within the assessment of severity of damage to health caused by effect of blunt or combined force.

Objective: This study aims to determine the value of mechanical violence that caused the injury using the Fortis system based on the detected range of injured soft tissue and the localization of the sites affected by said violence.

Material and Methods: In this experimental study the authors carried out measurements and calculations in 10 pedestrians, who died of polytrauma in an accident. The morphometric Ellipse v.2.0.7.1 software was used for the purpose (Vidito Kosice, Slovak Republic).

Results: The internal organ injuries were successfully evaluated in a planographic manner on serial sections with the following calculation of total extent of tissue damage (TETD). It turned out that if TETD is more than 40%, it will be possible to evaluate an injury as severe or life-threatening.

Conclusion: The above classification and localization of pedestrian injuries facilitate calculations in simulation programs to determine how the movement of a pedestrian's body during and after the collision occurred based on the unrepeatability of movement parameters; besides, contacts with a vehicle help determine the input data to calculate the collision. Based on the submitted case reports and performed measurements and calculations, the presented method of the extent classification of soft tissue damage is evaluated to be useful to standardize the injury parameters and assess polytrauma as a result of disproportionate force.

Citation: Bobrov N, Morochovič R, Mandelík J. Scope Assessment of Soft Tissue Injury within Polytrauma for Needs of Fortis System Injury Classification. *J Biomed Phys Eng*. 2021;11(3):315-324. doi: 10.31661/jbpe.v0i0.927.

Keywords

Pedestrians; Pedestrian Collision; Accidents, Traffic; Injury Parametrization System; Soft Tissue Injuries

Introduction

The forensic practice and the judicial engineering need a methodology specifying the severity of damage to both surface and deep soft tissues. The improvement of the methods for investigating injury parameters in traffic accidents has been the subject of expert discussion for many years. Not only forensic doctors, but also traumatologists and road transport experts have shown a serious interest in solving this problem.

¹MUDr, Department of Forensic Medicine, Faculty of Medicine of University Hospital of P. J. Safarik and University Hospital of L. Pasteur in Kosice, Slovak Republic
²MUDr, Associate Professor, Department of Traumatology, Faculty of Medicine of University Hospital of P. J. Safarik and University Hospital of L. Pasteur in Kosice, Slovak Republic
³PhD, Department of Transport Safety, University of Security Management in Kosice, Slovak Republic

*Corresponding author: Ján Mandelík
 University of Security Management in Kosice, ul. Kukucinova 17, 040 01 Kosice, Slovak Republic
 E-mail: emg@dodo.sk

Received: 15 April 2018
 Accepted: 8 June 2019

The extent and nature of organ and tissue injury are important to investigate severity of damage to health caused by the effect of blunt or combined violence. In case of death or injury to the most vulnerable road users, i.e. pedestrians, it is necessary to find out what injuries were involved in the immediate cause of death.

The data, which were obtained from the medical records of a participant who had a traffic accident (mostly it is a verbal description of injuries), cannot be useful for an accident analysis. From the medical point of view, any possible individual anatomic and physiological properties of a particular traffic accident participant also cause a justifiable caution of forensic surgeons to create a generally exact definition of physical characteristics. Therefore, it is appropriate for a forensic surgeon to comment on the parametrization of the found injuries only in terms of the consequences and not in terms of the causes. The quantification of injuries for each particular type of a traffic accident reflects the severity of injuries occurring during traffic accidents depending on the mechanical energy that caused the injuries.

The injury parameter means a certain virtual value expressing the nature, intensity, extent and severity of a particular type of body injury caused by mechanical violence. The most well-known injury parameters for evaluation systems are as follows [1]:

- Abbreviated Injury Scale – AIS,
- Injury Severity Score – ISS
- Gadd Severity Index – GSI,
- Head Injury Criterion – HIC,
- 3 ms Criterion – 3MS,
- Thoracic Trauma Index – TTI,
- Viscous Injury Response – VC,
- Extended Injury Criterion – EIC.

To determine the extent and severity of soft tissue damage as starting parameters, the data found by the AIS, ISS and VC scoring systems could be used. However, it has been proven that the traditional ways of evaluating injury

parameters such as AIS, ISS are inadequate in evaluating the extent of injuries in pedestrians–traffic accident participants, as the AIS/ISS parameters do not differ in value, especially with greater energies affecting the body [2,3]. The other systems of injury parameter evaluation are not utilizable in a uniform way for all body parts of an injured person. On the other hand, the output of the FORTIS system can be considered for an interdisciplinary procedure to prove a collision course between a vehicle and a pedestrian and a universal piece of information, which is offered by forensic surgeons, about the detected injuries to an accident analyst describing a complex spatial distribution and severity of pedestrian's injuries. Then, the analyst can compare those with the results of technical calculations performed by a simulation program and evaluate their accuracy, or correct the calculation, as the signs on a pedestrian's body and their distribution offer a unique evidence of an injury – collision, which always has a special course of contacts between a vehicle and a pedestrian [2,3].

In this work, based on the assessment of stated parameters in chosen casuistics, the authors present a new system of assessing the extent of soft tissue damage within the framework of the original FORTIS (Forensic Traumatology Injury Scale) scoring system in deceased pedestrians - traffic accident participants. The following damage to cutis and subcutis of a trunk, soft cranial tissue coverings, mesentery with respective fatty tissue, lungs and liver was quantified [4,5]. Unlike other systems of injury parameter evaluation, the FORTIS methodology reflects the extent of injuries more accurately.

Material and Methods

FORTIS system a demonstration of its use on examples

The FORTIS system defines the severity of injuries caused within polytrauma [6] dur-

ing traffic accidents of pedestrians depending on the location of contacts on a body surface (contact localization) and the equivalent of the mechanical energy (of the acting violence), which caused the injuries, stated in Fortis Points (FP). The system was developed by the Institute of Forensic Medicine of the Medical Faculty, UPJŠ, and used in the forensic practice in the Slovak Republic for several years [7].

As to the FORTIS system, it is shown how to use it as follows:

Example 1

Patient XX, 23 years old

Basic damage to health – verbal description:

- Contusion of the soft tissue in the lumbo-sacral area and pelvis in the area of both hip joints.
- Contusion of the hairy part of the head in the occipital area.
- Multiple surface injuries (cutaneous abrasions and minor cuts) of the left shoulder, arm, elbow and wrist.
- Contusion of the soft tissue of the left chest.

Complications:

- Oedema of the soft tissue in the occipital area and both hip joints.
- Spontaneous pain in the left lower ribs.

Related findings: The patient left the

health care facility on 18th September 2016 at about 6:30 p.m. out of choice.

Associated diseases: Unidentified.

Secondary findings: Unidentified.

The injuries of **XX, 23 years old**, are quantified and localized by the FORTIS system as follows (Table 1, Figure 1):

The localization and designation of the injury parameters in FP - XX, 23 years old, according to the individual body parts are shown in Figure 1.

Example 2

Deceased EE, 75 years old

- Skin abrasions: in the parietal-occipital area of head, in the middle, 3 on the front-outer area of the middle third of the right arm and 3 on the rear area of the left elbow,
- Suffusions of blood: on both upper eyelids and the front-outer area of the middle third of the right arm,
- Lacerated and bruised wound in the parietal-occipital area of head, in the middle (surgically treated),
- Haemorrhage/bleeding through the soft cranial coverings in the frontal-parietal area, bilateral, and in the parietal-occipital area, bilateral,
- Fracture of the bones of the cranial vault and base: frontal bone, ethmoid bone, both parietal bones and occipital bone,
- Contusion of the base of both frontal, tem-

Table 1: Scoring of XX, 23 years old.

Ord. No.	Injury description of C, 23 years old	FORTIS points of basic damage to health (FP-BDH)
1	Contusion of the soft tissue in the lumbo-sacral area and pelvis in the area of both hip joints	0.6
2	Contusion of the hairy part of the head in the occipital area	0.1
3	Multiple surface injuries (cutaneous abrasions and minor cuts) of the left shoulder, arm, elbow and wrist	0.4
4	Contusion of the soft tissue of the left chest	0.2
Total FORTIS scoring according to categories (FP-BDH)		1.3

FP-BDH: FORTIS points of the basic damage to health

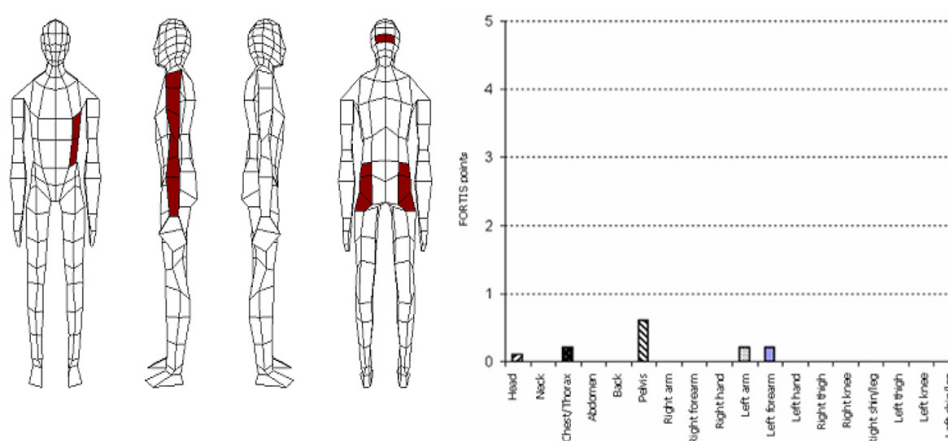


Figure 1: Localization, quantification and individual graphic representation (signature) of injuries of XX, 23 years old, detected using the FORTIS scoring system. The total injury evaluation is 1.3 FORTIS points.

poral and parietal brain lobes,

- Bleeding under dura mater in the frontal-parietal-temporal-occipital area of the brain, on the right – clinical datum,
- Residual bleeding under dura mater in the anterior and middle cranial fossa on the left, and in the anterior, middle and posterior cranial fossa on the right (80 g of blood),
- Diffuse bleeding between the soft meninges (arachnoid),
- Cerebral oedema with pressure cones.

The injuries of EE, 75 years old, are quantified and localized by the FORTIS system as follows (Table 2, Figure 2):

Scoring of EE, 75 years old

The localization and designation of the injury parameters in FP- EE, 75 years old, according to the individual body parts are shown in Figure 2.

The FORTIS system has the following instructions for the assessment of contusion:

- Blunt force cutaneous and subcutaneous injuries for each 100 cm²: 0.2 FP (Fortis Points)
- Blunt force muscle injuries for each 10 cm²: 0.2 FP

The damaged area is to be determined with a reasonable accuracy.

Total extent of tissue damage (TETD) as an injury parametrization value

In this experimental study, the quality of the input parameters, which is ensured by the text, photographic and video documentation of the external and internal post-mortem examination in the autopsy room, is crucial for a trouble-free evaluation of the soft tissue damage extent. Therefore, it was decided to take the advantage of new morphometric software - Ellipse v. 2.0.7.1 by ViDiTo (Kosice, Slovak Republic) in order to detect the total area of surface injuries and total volume of deep injuries, introducing a new value into practice – the total extent of tissue damage (TETD). In the morphometric analysis, the instructions given in the *Atlas kvantitatívni histologie (Quantitative histology)*, Z. Tonar, 2008 [8] were used. In the forensic assessment of the selected caustics using the described method, it was necessary to provide a structured forensic diagnosis, the scheme of which is a carefully worked-out output based on the guideline of the International Classification of diseases (ICD, 10th revision) and consists of 5 items as follows:

Table 2: The injuries of the aforementioned person according to their localization, extent and severity are quantified and localized as follows

Ord. No.	Injury description	FORTIS points of basic damage to health (FP-BDH)
1.	Skin abrasion in the parietal-occipital area of head, in the middle	0.1
2.	Lacerated and bruised wound in the parietal-occipital area of head, in the middle (surgically treated)	0.3
3.	Haemorrhage/bleeding through the soft cranial coverings in the frontal-parietal area, bilateral	0.3
4.	Haemorrhage/bleeding through the soft cranial coverings in the parietal-occipital area, bilateral	0.3
5.	Suffusions of blood on both upper eyelids	0.2
6.	Fracture of the frontal bone on the right with the continuation of the fracture line between both parietal bones in the course of the sagittal suture and to the occipital bone on the left	1.8
7.	Fracture of the ethmoid bone	1.0
8.	Fractures of the facial bones forming eye sockets	1.2
9.	Contusion of the base of both frontal, temporal and parietal brain lobes	2.8
10.	Local contusion of both lungs in the back segment area, more to the left	1.4
11.	3 skin abrasions on the front-outer area of the middle third of the right arm	0.2
12.	Suffusion of blood on the front-outer area of the middle third of the right arm	After handling the patient's body
13.	3 skin abrasions on the back of the left elbow	0.2
Total FORTIS scoring according to categories (FP-BDH)		9.8

FP-BDH: FORTIS points of the basic damage to health

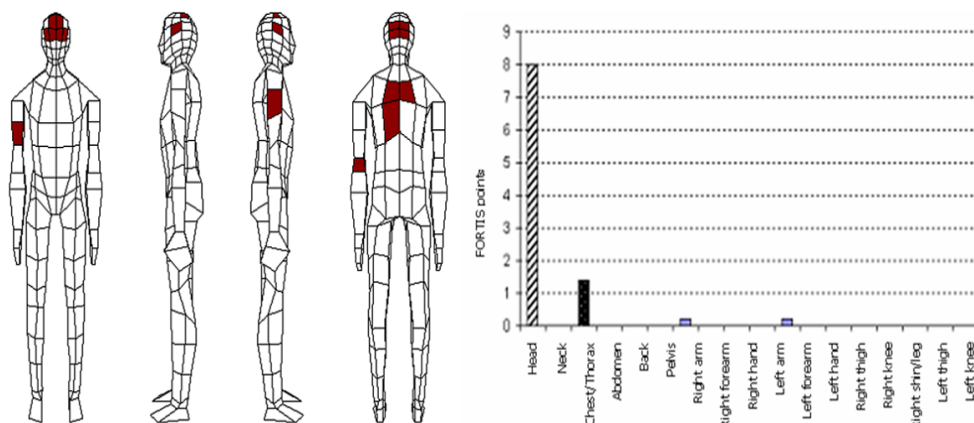


Figure 2: Localization, quantification and individual graphic representation (signature) of injuries of EE, 75 years old, detected using the FORTIS scoring system. The total injury evaluation is 9.8 FORTIS points of the basic damage to health (FP-BDH).

1. Immediate cause of death
2. Basic damage to health
3. Complications and related findings
4. Associated damage to health
5. Secondary finding.

According to the presented scheme, the forensic diagnosis enables a logical separation of forensically significant injuries from other damage to health, including early and long-term consequences of injury, complications of provided health care as well as the damage to health existing before the traffic accident.

Evaluation and calculation of total extent of tissue damage

In this experimental study, based on casuistic, the total extent of soft tissue damage (cutis and subcutis, soft cranial coverings, mesentery with respective fatty tissue, lungs and liver) was calculated in 10 pedestrians, who died as a result of polytrauma in a traffic accident. To evaluate the extent of damage, the Ellipse v. 2.0.7.1 morphometric software (ViDiTo Kosice, Slovak Republic) [9] was used applying the methodologies by Tonar (2008) [8]. The total extent of tissue damage (TETD) in each individual was calculated in two ways, including contouring and planography, followed by a morphometric analysis. The planographic way was carried out using the following formula:

$$CPRT(\%) = \frac{\sum h_i \times w_i \times d_i}{\sum h_0 \times w_0 \times d_{0 \times I_{tv}}} \times n^{-1} \quad (1)$$

Where h, w, d are the dimensions of an injury (i) and an entire organ or structure (0), respectively and I_{tv} is organ or structure shape index (index value of 0,6 - 0,8) as well as n is number of examined sections or sectors [9].

The described methods were used to evaluate skin abrasions, suffusions of blood, lacerated and bruised wounds and local contusions. Subsequently, in each case, the FORTIS quantification methodology was used to quantify the severity of injuries and calculate the injury

signatures of 16 anatomic body locations. To evaluate the extent of area skin injuries, the body mass index was used as an initial parameter.

Results

The most common injuries to the skin and subcutaneous fatty tissue, including skin abrasions and suffusions of blood, were quantified based on the photo documentation analysis during the external examination in the autopsy room. The contouring of injury extent evaluation using the Ellipse morphometric software was proven to be efficient, especially in case of fragmented area skin abrasions with well-contoured edges (Figures 3 and 4).

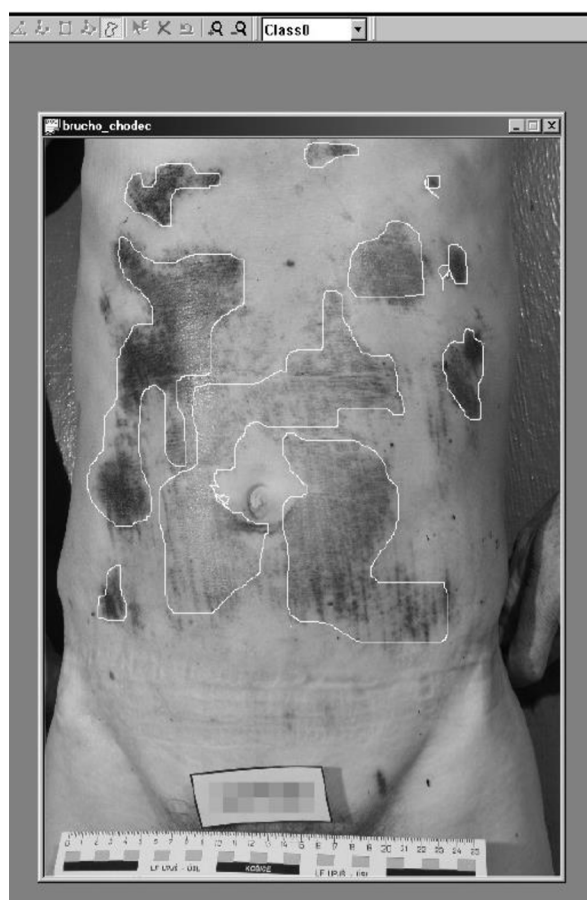

Figure 3: Skin abrasions in the abdominal area processed by a *freehand* contouring tool in Ellipse v. 2.0.7.1.




Figure 4: Suffusion of blood in the left lumbar area processed by a *freehand* contouring tool in Ellipse v. 2.0.7.1 with an automatic calculation of the total area and circumference of the injury.

When evaluating suffusions of blood with blurred edges, there were certain difficulties with the use of contouring tools, such as *dot-to-dot* and *freehand*. The accurate determination of the damage extent was only possible in case of calibrating the dimensions of the examined objects (necessary presence of a scale on overall, semi-detailed and detailed images).

When assessing the damage to the soft cranial coverings of a contusion and bleeding nature, the most complex task was to calculate the total area of soft tissue and estimate the

depth of damage in the peripheral sections.

It should be noted that the total damage area can be calculated automatically not only in metric units (mm², cm²), but also in actual screen resolution units—in pixels, which is an important property of the program in evaluating and comparing uncalibrated photoshots.

The internal organ injuries were successfully evaluated in a planographic way on serial sections, followed by the calculation of the total extent of tissue damage (TETD) (Figures 5 and 6).

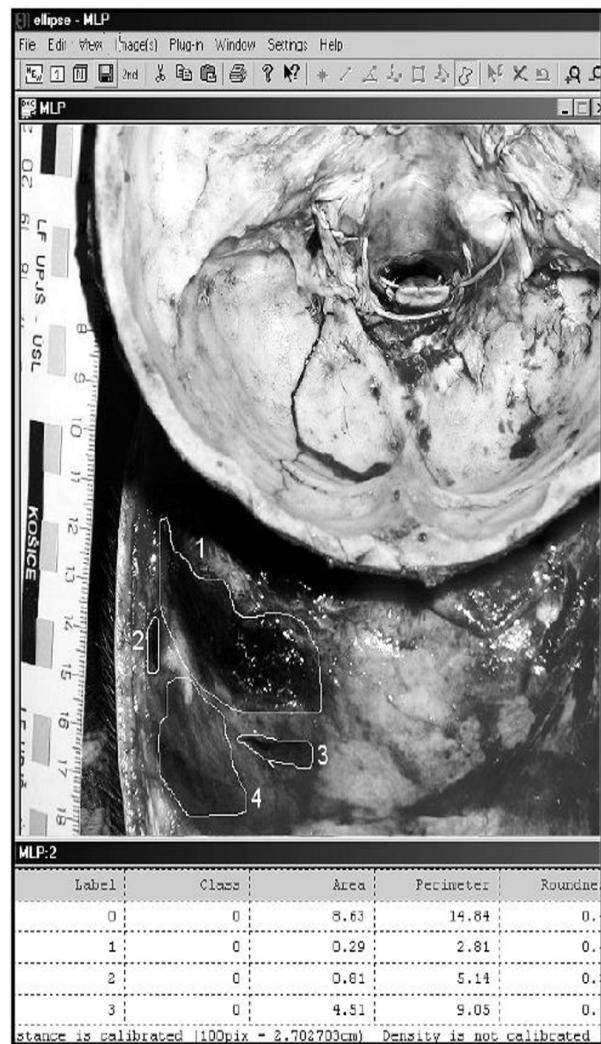

Figure 5: Bleeding through the soft cranial coverings (locations 1... 4) in Ellipse v. 2.0.7.1.

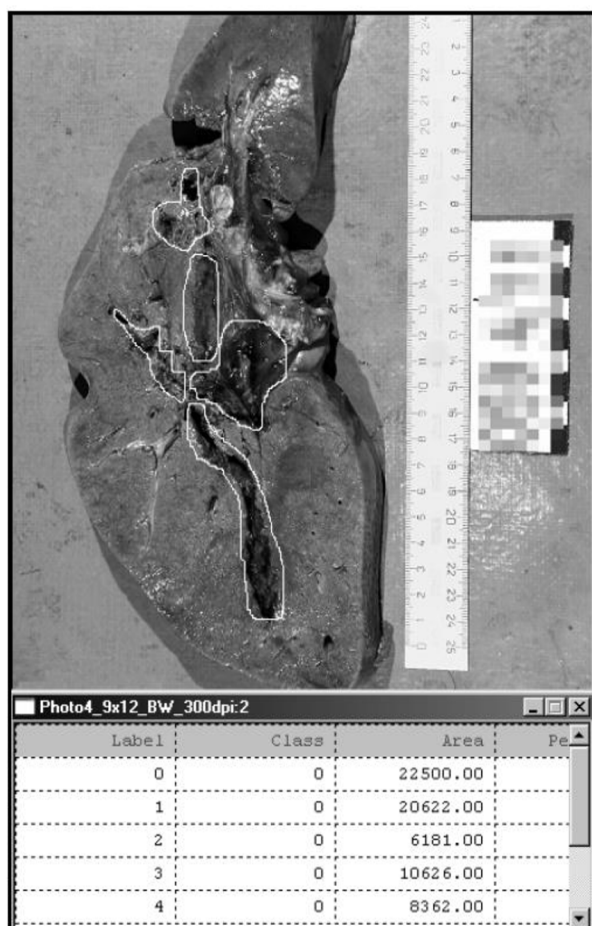


Figure 6: Determination of total extent of tissue damage (TETD) (contusion, fissures) of the liver in Ellipse v. 2.0.7.1.

It turned out that with TETD more than 40%, it is possible to evaluate the damage in case of a vital organ, as severe or life-threatening (value of AIS points 4 - 5, ISS from 66 – so-called “major trauma”).

All evaluated injuries were parts of basic damage to health within the polytrauma. In Table 3, there is a summary of the examined cases with the injury quantification according to the FORTIS system (used abbreviations: V - van, PV –passenger vehicle, L - lorry, BDH–basic damage to health) [10,11].

Discussion

The standardization methodology of injury parameters for pedestrians in traffic accidents (injury quantification) requires the application of scoring (point) evaluation systems allowing (with standard initial parameters) to calculate the severity of basic damage to health, direct post-traumatic complications and related complications, including painful treatment procedures and health care of poor quality. In addition, in case of fatal injuries, it is possible to determine the damage to health, which is the immediate cause of death [6]. Based on the injury assessment, we could divide injuries into

Table 3: Summary of the examined cases with the injury quantification according to the FORTIS system.

Case No.	Name, Age	M/W	Vehicle	Survival time (hours)	ISS	FORTIS BDH
1	P.U., 41	M	V	0	66	22.4
2	M.J., 38	M	PV	0	75	47.7
3	A.P., 67	W	PV	0	75	53.6
4	E.P., 9	M	PV	0	75	41.1
5	P.S., 49	M	L	0	75	65.3
6	A.Č., 80	W	PV	0.8	57	66.2
7	J.N., 58	M	PV	2	75	77.4
8	J.B., 57	M	PV	24	75	60.8
9	I.M., 47	M	PV	72	75	46.9
10	Š.CH., 57	M	L	239	75	19.1

BDH: Basic damage to health, ISS: Injury severity score

minor, medium, severe and life-threatening ones, with the appropriate quantification. In case of a survival, a possibility to predict a prognosis of health condition development to a certain extent appears to be significant.

Based on this standardization of injury parameters, it will also be possible to distinguish a degree of a person's fault in causing a traffic accident from other circumstances such as an irresponsible attitude of an injured person or inadequate treatment of incurred injuries.

Conclusion

Although this methodology is significant to evaluate polytrauma, it may not be used to evaluate the injuries arising from other death patterns, such as asphyxia, drowning, as in these cases injuries are not caused by excessive force acting on a body as a whole. Since there is no polytrauma, a pathological and anatomical finding of a forensic autopsy lacks the information as compared with polytrauma. As a result, it cannot be expressly quantified using the FORTIS method.

The elaborated methodology for evaluating the soft tissue damage is compatible with the procedure recommended by the European Association for Accident Research and Analysis (EVU) for member states of the European Union, demonstrating new possibilities to visualize external and internal injuries of a human body according to the principles of Evidence-Based Medicine (EBM).

Acknowledgment

The authors of the publication are not in a mutual conflict of interests and they agree with its publication. The manuscript is not in a conflict of interests with any natural or legal entity.

Ethical clearance: No special ethics approval is needed, the information shared to the Ethics committee, Faculty of Medicine, P. J. Safarik University in Kosice, Slovak Republic.

The authors, themselves without any other

support, funded the presented research.

Conflict of Interest

None

References

1. Baker SP, Ginsburg MJ, Li G, O'Neill B. The injury fact book. Oxford: Oxford University Press; 1984. p. 190.
2. Bobrov N, Longauer F, Mandelík J. Documentation of fatal road traffic injuries – a new approach by FORTEST method. 2th Congress of International Academy of Legal Medicine; Budapest (Hungary); 2006.
3. Bobrov N, Mandelík J, Havaj P. Possibilities of judiciary accident assessment and its use in the interdisciplinary investigation of traffic accidents. Košice; 2017. p. 225.
4. World Health Organization. 10th Revision of the International Statistical Classification of Diseases and Related Health Problems. Bratislava, Obzor: WHO; 1994. p. 1-822.
5. Sharma B, Harish D, Bangar S, Singh VP. Trauma score: A valuable tool for documentation of autopsy reports of trauma victims. *Journal of Indian Academy of Forensic Medicine*. 2005;27:77-81.
6. Šramo J. Biomechanics and methods of injury parameter investigation. Conference of experts in field of road transport with foreign participation – Collection of lectures. Nitra: 2002. p. 86-96.
7. Mandelík J. Pedestrian's injury parametrization and its usage in description of traffic accidents. Žilina: University of Žilina; 2006.
8. Tonar Z. Atlas Quantitative histology, Institute of Histology and embryology. Faculty of Medicine in Pilsen: 2008. p. 111. Available From: http://www.ellipse.sk/Doc/atlas_kvantit_histologie_lowres.pdf.
9. Internet homepage of Ellipse software (developed by ViDiTo, Košice, Slovakia). 2010. Available From: <http://www.ellipse.sk/>.
10. Kelemen M., Bobrov N., Mandelík J. Havaj P. Parametrization of pedestrians by the FORTIS system, possibilities for its utilisation at solving accidents and at detecting traffic accidents by using PC Crash Singapur. International

Conference on Forensics Science; Criminalistics Research (FSCR); 2014.

11. Mandelík J, Bobrov N, Nevolná Z. Parametrization of Pedestrian Injuries and its Utilisation in

Proving Traffic Accidents Course Using Injury Signatures and Contact Signatures. *J Biomed Phys Eng.* 2019;**9**(1):3-16. PubMed PMID: 30881930. PubMed PMCID: PMC6409379.